

20 November 2024

Matamata Veterinary  
Services Ltd  
362 Hinuera Road West  
RD2, Matamata 3472  
New Zealand  
Tel 07 888 8193

## SURGICAL REPORT

**Re: Maddison's Delight – Downbytheseaside 2023**  
**Microchip:** 985100012202142  
**Agent:** Woodlands Stud  
**Owner:** Paul and Mary Kenny

On 20 November 2024 the above described colt underwent arthroscopic surgery of the right hock to explore the source of tibiotarsal joint effusion. A routine dorsal approach was made to the joint. Two free fragments of cartilage were removed from the synovium of the tibiotarsal joint. A small fibro-osseus lesion was removed from the axial aspect of the medial malleolus and underlying bone was debrided to healthy margins. The joint was flushed and portals were closed routinely.

### Management:

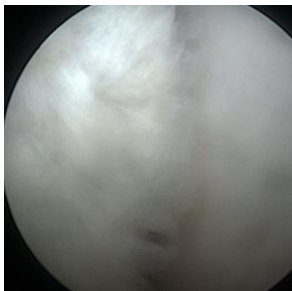
1. Rest: please maintain the horse on box rest for two weeks followed by two weeks in a small yard.
2. Bute: give 8ml by mouth once a day for three days starting 22 November 2024.
3. Suture removal: please have sutures removed 2 December 2024.
4. Bandaging: please have the bandage changed every four days for three more bandage changes. The next bandage change is due on 25 November 2024.
5. We recommend the use of Pentosan in the muscle and 4-Cyte in feed to encourage growth of healthy new cartilage in the three months following surgery. It is recommended to start this at suture removal.

Intravenous and intramuscular injections have been administered to this horse. Please monitor the catheter, injection sites, and incisions closely. Please contact the MVS Equine Hospital if there are any signs of heat, pain, swelling and/or discharge.

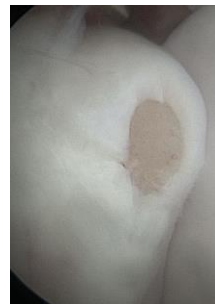Yours sincerely



Barbara Hunter DVM MS MANZCVS DACVS-LA  
Registered Specialist in Equine Surgery



*Fibro-osseus lesion Right Medial Malleolus*



*Post-Debridement*

*Please ensure that this report is forwarded to the horse's owner(s) and the person(s) responsible for the future care of the horse, as well as to the insurer, if applicable.*